

The Usefulness of Children's Drawings in the Diagnosis of Headache

Carl E. Stafstrom, MD, PhD*‡; Kevin Rostasy, MD*; and Anna Minster, MD*

ABSTRACT. *Objective.* To determine whether drawings can aid in the differential diagnosis of headaches in children.

Methods. Before taking any history, 226 children who were seen consecutively for the evaluation of headache were asked to draw a picture to show how their headache felt. The pictures were then scored as migraine or nonmigraine by pediatric neurologists who were blinded to the clinical history. A clinical diagnosis of headache type was determined independently by another pediatric neurologist using the usual history and examination. The diagnoses of headache type based on the pictures drawn and the clinical findings obtained were then compared to calculate the sensitivity, specificity, and predictive values of the drawings for the diagnosis of migraine.

Results. Children produced dramatic and insightful headache drawings. Compared with the clinical diagnosis (gold standard), headache drawings had a sensitivity of 93.1%, a specificity of 82.7%, and a positive predictive value (PPV) of 87.1% for migraine. That is, drawings that contained an artistic feature consistent with migraine (eg, pounding pain, nausea/vomiting, desire to lie down, periorbital pain, photophobia, visual scotoma) predicted the clinical diagnosis of migraine in 87.1% of cases. Predictive values were also calculated for specific migraine-associated features on drawings: artistic depiction of focal neurologic signs, periorbital pain, recumbency, visual symptoms (photophobia, scotomata), or nausea/vomiting had a PPV of >90% for migraine; severe or pounding pain had a PPV of >80% for migraine. Band-like pain was not predictive of migraine (PPV of 11.1%). Features on drawings such as sadness or crying did not differentiate migraine from nonmigraine headaches.

Conclusions. Children's headache drawings are a simple, inexpensive aid in the diagnosis of headache type, with a very high sensitivity, specificity, and predictive value for migraine versus nonmigraine headaches. We encourage the use of drawings in the evaluation of any child with a headache, as an adjunct to the clinical history and physical examination. *Pediatrics* 2002;109:460-472; *headache, migraine, children, drawings, art.*

ABBREVIATIONS. IHS, International Headache Society; PLR, positive likelihood ratio; PPV, positive predictive value.

From the *Departments of Pediatrics and Neurology, Division of Pediatric Neurology, Floating Hospital for Children, New England Medical Center, Tufts University School of Medicine, Boston, Massachusetts; and ‡Departments of Neurology and Pediatrics, University of Wisconsin, Madison, Wisconsin.

Received for publication Jun 4, 2001; accepted Aug 28, 2001.

Reprint requests to (C.E.S.) Department of Neurology, University of Wisconsin, H6-528, 600 Highland Ave, Madison, WI 53792. E-mail: stafstrom@neurology.wisc.edu

PEDIATRICS (ISSN 0031 4005). Copyright © 2002 by the American Academy of Pediatrics.

Headache is one of the most common presenting complaints in pediatrics and is a frequent reason for referral to pediatric neurologists. As many as two thirds of children complain of headache severe enough to seek medical attention at some point during childhood.¹ The prevalence of migraine in childhood is high, ranging from 2% to 11% in various population studies.¹⁻⁵ These figures vary by age, gender, study population, method of assessment, and diagnostic criteria. Migraine and tension-type headaches together compose the majority of cases of childhood headache. Some studies suggest that the incidence of both migraine and nonmigraine headache is increasing over time.^{6,7}

Despite the high frequency of headaches in childhood, determining their cause can be difficult.⁸ Headaches are traditionally divided into migraine and nonmigraine; nonmigraine headaches are further subdivided into tension-type headaches and those with secondary causes (eg, attributable to tumor, head trauma, intracranial hypertension). Headache type remains a clinical determination, and physicians must rely primarily on a detailed history to arrive at the correct diagnosis. No imaging modality, blood test, or other study is available to differentiate between migraine and nonmigraine headaches. An accurate diagnosis is critical, because treatment approaches differ depending on the headache cause.

Although several classification schemes to diagnose migraine and other headache types have been published,⁹⁻¹¹ the process of headache diagnosis is often idiosyncratic, dependent on the clinician's training and subjective biases.¹² Most headache experts agree that the diagnosis of migraine requires recurrent, paroxysmal headaches with headache-free intervals, plus at least 2 additional symptoms, such as aura, nausea/vomiting, family history of migraine in the parents or siblings, throbbing quality, unilateral location, and relief by sleep.¹³ The International Headache Society (IHS) has published criteria for the diagnosis of various headache types in adults,¹¹ with the goal of standardizing diagnostic criteria for the purposes of research and clinical trials. It was proposed that these criteria could be applied in the clinical setting as well. For migraine without aura, these criteria include at least 5 headaches lasting 2 to 48 hours plus at least 2 of the following: unilateral location, pulsating quality, moderate or severe intensity, aggravation by routine physical activity, plus at least 1 of the following: nausea or vomiting, or photophobia and phonophobia. To optimize the sensitivity of the IHS criteria while maintaining their high specificity for children, several revisions to the orig-

inal criteria have been suggested.^{3,14-18} These modifications include reduction of the minimum duration from 2 hours to 1 hour, reduction of the number of required episodes from 5 to 3, and elimination of the requirement for unilaterality. It is uncertain how strictly the various criteria are applied in general practice, and the determination of headache type remains a clinical judgment.

Pediatricians face additional diagnostic challenges when confronted with a child with headaches. Children, especially younger ones, may have difficulty explaining their symptoms verbally. Even adolescents have difficulty describing their headaches; in 1 study, 25% of children between 9½ and 16 years of age were unable to provide information about even 1 headache characteristic.¹⁹ In addition, the manifestations of a headache syndrome may change over development, reflecting the evolution of headache pathophysiologic mechanisms in the growing child. For example, cyclic vomiting and benign paroxysmal vertigo are conditions in young children that rarely present as headache yet are well recognized as migraine "equivalents" or precursors.²⁰⁻²² In children, compared with adults, migraines are shorter, less often unilateral, less likely to include a visual aura, and more likely to involve constitutional symptoms (nausea and vomiting, flushing, pallor).^{12,23}

Children are often expressive artists, and they can sometimes communicate more effectively through pictures than verbally.²⁴ Drawings have been used for decades by child psychiatrists and psychologists to analyze children's subjective feelings, subconscious concerns, fears, and other emotions.^{25,26} Artwork has been used to investigate children's attitudes toward painful procedures,²⁷ self-perception in chronic conditions such as asthma²⁸ and sickle cell disease,²⁹ emotional responses after physical or sexual abuse,³⁰ and perceptions of acute or chronic orthopedic pain.³¹

Surprisingly, children's drawings have been underused in headache diagnosis. Adult migraineurs, many of them professional artists, have produced elaborate artistic impressions of their headaches that have been popularized through international migraine art competitions.³² Insights into various aspects of migraine pathophysiology are emerging from detailed analysis of individual pictures from this archive.³³⁻³⁶

A few authors have also published children's headache drawings to investigate the subjective feelings of children with headaches,^{37,38} to describe migraine visual auras,^{39,40} or to illustrate headache severity.⁴¹⁻⁴³ To our knowledge, however, there has been no attempt to analyze children's headache drawings systematically as an aid in headache differential diagnosis. Such a technique could be used to support a clinical diagnosis, suggest that another cause be considered, and guide therapeutic decision making. We hypothesized that children's drawings would be a simple, inexpensive adjunctive tool for the diagnosis of headache in children and adolescents. Preliminary results have been presented in abstract form.⁴⁴

METHODS

A total of 226 consecutive children with the chief complaint of headache were evaluated at the senior author's (C.E.S.) pediatric neurology clinic at the Floating Hospital for Children, Tufts University School of Medicine (Boston, MA). The children were referred by primary care physicians (pediatricians, family practitioners) or pediatric neurologists in the greater Boston area. The demographics of the children encompassed a varied socioeconomic range, and there was no specific ethnic, geographic, or racial predominance.

The method of obtaining drawings was as follows. At the beginning of the visit, before any history was obtained from the child or parent, each child was provided with a blank, unlined piece of white paper (8.5 × 11 inches) and a number 2 pencil with an eraser. The child was then asked to "Please draw a picture of yourself having a headache. Where is your pain? What does your pain feel like? Are there any other changes or symptoms that come before or during your headache that you can show me in a picture?" To minimize bias, no leading questions or additional instructions were given. Most children participated willingly; the remainder complied after a bit of encouragement. There were no refusals. Additional embellishment of the drawing (eg, words of explanation, labels) was neither encouraged nor prohibited, and many children added such explanatory notes to their picture. When the child complained of more than 1 type of headache, he or she was asked to draw a separate picture depicting each type. The children were allowed as much time as needed to complete the drawing, but most completed their picture in only a few minutes. While the child drew, the examiner spoke with the parent about the child's medical history (birth, development, etc) and avoided discussion of issues specifically related to headache. After the picture was complete to the child's satisfaction, it was set aside (not viewed by the examining neurologist), then the usual clinical evaluation was performed (history, physical examination, formulation, and management plan). On the basis of this clinical evaluation, a clinical diagnosis of headache type was made, and a management plan was discussed with the parent and the child. For purposes of this study, the child's headache (or headaches, if more than 1 type) was categorized as migraine or nonmigraine. This headache diagnosis was determined solely on clinical grounds, without reference to any specific criteria such as those of the IHS.¹¹ As such, this diagnosis is dependent on the clinical impression of the senior neurologist (C.E.S.), based on experience and published general guidelines.^{8-10,12,13,22} At the end of the visit (after the clinical diagnosis was made), the child was asked to explain his or her drawing, and notes were made about the child's interpretation.

Later, the drawings were analyzed independently by 2 pediatric neurologists (K.R., A.M.) who were blind to the clinical history. These raters were asked to evaluate each drawing and decide, on the basis of their own clinical experience, whether the picture contained features more consistent with migraine or nonmigraine headache. Specific migraine features would include depiction of severe pain, especially if it had a pounding, pulsatile, or throbbing character; nausea or vomiting; sensitivity to light or sound (phonophobia or photophobia); recumbency or desire to sleep; exacerbation by exercise or movement; associated autonomic features (pallor, diaphoresis); focal neurologic signs or symptoms (paresthesias, weakness); confusion or other change in mental status; or clear-cut unilaterality of pain or other symptoms or signs. Raters were advised to use their clinical judgment to determine whether the picture contained migraine features, rather than predetermined criteria. The study was thus designed to mimic the clinical practice situation in which a practitioner would use the drawing as part of the clinical evaluation.

Interrater reliability was assessed using the κ statistic. κ , defined as the actual interrater agreement beyond chance divided by the potential interrater agreement beyond chance, corrects for chance agreement between raters.⁴⁵ Expressed mathematically, $\kappa = (O - C)/(1 - C)$, where O is the observed agreement and C is the chance agreement.

Each child was therefore assigned 2 headache diagnoses independently, one a clinical diagnosis based on history and examination and the other a drawing diagnosis based on blind analysis of the headache drawing. The clinical diagnosis (by C.E.S.) was considered the "gold standard" to which the headache drawing diagnosis was compared. Therefore, with regard to migraine, a

“true positive” would be the case in which both the clinical and the artistic diagnoses suggested migraine, a “true negative” would be the case of neither the clinical diagnosis nor the drawing suggesting migraine, a “false positive” would be if the drawing contained features suggestive of migraine but the clinical diagnosis did not, and a “false negative” would be if the clinical assessment was migraine but the drawing contained no features suggestive of migraine. From these data, we derived the sensitivity, specificity, and positive and negative predictive values of children’s drawings as a diagnostic adjunct for the diagnosis of migraine. In addition, the positive likelihood ratio (PLR) was calculated; the PLR represents the odds of obtaining a migraine drawing among children with a clinical diagnosis of migraine, compared with the odds of a migraine drawing among children without a clinical diagnosis of migraine.⁴⁶

RESULTS

A total of 226 children participated in the study. Each child produced at least 1 headache drawing; 9 children drew 2 pictures, corresponding to 2 distinct headache types. Therefore, 235 drawings by 226 children were analyzed. Ages of participants ranged from 4 to 19 years (mean \pm standard deviation: 11.4 ± 3.4 years). There were 105 boys and 121 girls. Of these 226 children, 130 (57.5%) were given the clinical diagnosis of migraine or mixed headache with a prominent migraine component; the remaining 96 children had nonmigraine headaches attributable to a variety of causes (see below).

Examples of Headache Drawings

Several figures are presented to illustrate the various categories of headache drawing. The drawings were not altered or retouched, although their sizes were sometimes altered digitally to make them more proportionate for clarity of presentation.

Figures 1 to 4 show examples of drawings considered to represent migraine headaches. A total of 139 drawings were categorized as migraine, comprising those in children who received the clinical diagnosis of migraine (true positives) plus those whose drawings contained migraine features but did not receive the clinical diagnosis of migraine (false positives).

The artistic depictions of pain were often dramatic. Figure 1 shows examples of pounding or throbbing pain, a feature seen in 61.9% (86/139) of drawings rated as migraine (true positives plus false positives). Objects that inflict pounding pain included hammers, baseball bats, rocks, bricks, drumsticks, bottles, golf clubs, and fists. Other drawings depicted severe pain, inflicted by such objects as knives, rocks, vise grips, saws, high-heeled shoes, anvils, and chairs. The most severe pain was illustrated by exploding heads, firecrackers, volcanoes, lightening bolts, jackhammers, and even decapitation. Pain was perceived as coming from outside (Figs 1A to 1D) or inside (Figs 1E and 1F) the head. One girl drew a rubber reflex hammer striking her forehead (to the delight of the pediatric neurologists!) (Fig 1D). This girl obviously had a previous neurologic examination and now associates her throbbing pain with the instrument used to test tendon reflexes. The throbbing nature of the pain is underscored in Figs 1B and 1D, where lines of motion emphasize the pounding sensation. The child who drew Fig 1C was asked the meaning of the question mark on his abdomen, as the

examiner wondered whether this represented a gastrointestinal symptom; however, the child replied that the question mark indicated the trademark of a popular brand of clothing. The graphic verbal outburst accompanying his picture, an indication of pain severity, defies additional comment!

Visual symptoms (40 [28.8%] of 139 migraine drawings) were often expressed vividly (Fig 2) and included flashing white or colored spots moving across the visual field and scintillating shapes. (The drawing with colored spots moving across the visual field [not shown] was labeled by the child as having different colors; no colored pencils were used.) Photophobia was portrayed by closed eyes, shut-off lamps, or eyes covered with a blanket or face cloth. In Fig 2A, photophobia is indicated by a line crossing out the sun, and sonophobia is expressed by the crossed out radio. In Fig 2B, the child indicated that the lightbulb in the upper right of the picture caused colored dots to appear on the left side of his vision; he also felt nauseated, indicated by his hand holding his stomach. The girl who drew Fig 2C experienced scintillating scotomata on the right side of her visual field, whereas the girl who drew Fig 2D saw similar forms on the left. Before a headache began, the boy who drew Fig 2E stated that objects straight in front of him were seen clearly (desk, television set), whereas objects off to the far left side were blurry (in this case, a distorted door). The boy who drew Fig 1F explained that initially (before the headache), he had a clear field of vision (left side of picture), but over time (arrow), he perceived moving shiny circular spots traversing his visual field.

Gastrointestinal symptoms were drawn relatively infrequently (10 [7.2%] of 139 migraine drawings), but when present, they were unmistakable. Figures 3A to 3D show examples of gastrointestinal distress and vomiting. The girl who drew Fig 3A described pounding pain in the right temple (arrow), sensitivity to light (eyes shut), and nausea. Turbulence in her stomach is depicted by wavy lines, and lack of appetite is suggested by crossing out the word “food.” Figure 3B was drawn by a girl with unilateral left-sided head pain accompanied by nausea (“yuck”). The 2 illustrations of active vomiting (Figs 3C and 3D) are self-explanatory.

The desire to lie down is frequently mentioned by migraine sufferers. Several children drew themselves recumbent or asleep (20 [14.4%] of 139 migraine drawings), some in association with other symptoms such as pounding (Fig 3E), photophobia (eg, cloth over face), or nausea. In Fig 3F, the girl is recumbent with a sad facial expression, although no specific indication of pain is drawn.

Figure 4 illustrates examples of focal neurologic abnormalities (7 [5.0%] of 139 migraine drawings). These renderings were startling in their appearance and anatomic detail. The boy who drew Fig 4A described sensations of pins and needles beginning on half of his face, then spreading down his arm and leg, followed several minutes later by a headache; there is a strong family history of hemiplegic migraine (father, grandfather). The girl who drew Fig 4B explained that she had pounding pain on the left




Fig 1. Examples of pounding pain. A, A 9-year-old boy depicts pounding pain inflicted by a hammer and chisel. Note the chiseled appearance of his skull. B, A 14-year-old girl shows a baseball bat pounding her head. C, A 15-year-old boy expresses pain from a hammer and utters profanity. D, A 12-year-old girl shows throbbing midfrontal pain resembling pounding of a reflex hammer. E, A 10-year-old boy illustrates throbbing pain “like a drum set in my brain.” F, A 14-year-old boy depicts pain inflicted by an intracranial figure pounding with a hammer; note indentation in his forehead caused by the hammer. All of these pictures were rated as migraine, both clinically and by drawing.

(“truck ramming my head”) and “floaty feelings” (note human figure “floating” near left temple). At the same time, she felt sharp, prickly feelings on the right side of her mouth and right hand. In this case, the focal neurologic deficits occurred contralateral to the headache. The child who drew Fig 4C explained similar sharp, pin-like sensations on the left side of

his face only. The children who drew Figs 4B and 4C insisted that the paresthesias never crossed the midline, indicated by the lines bisecting their faces.

All of the above pictures were rated as consistent with migraines. Drawings categorized as more consistent with nonmigraine headaches were often equally as dramatic but failed to include typical mi-




Fig 2. Examples of visual phenomena accompanying headaches. A, A 16-year-old girl shows photophobia (line crossing out the sun), sonophobia (line crossing out a radio), and bitemporal pain (two X's). B, A 12-year-old girl shows a lightbulb in the upper left associated with sparkling spots in the left visual field. She also shows left temporal pain (lines emanating from that area) and nausea (holding stomach). C, A 9-year-old girl draws a scintillating scotoma in the right visual field. D, A 10-year-old girl shows scintillating scotoma in the left visual field as if projected onto a screen. E, A 14-year-old boy draws his left visual field showing a rim of blurriness with central objects (desk, television) seen clearly; at the far left, a door is shown in a distorted manner. F, A 14-year-old boy depicts a normal visual field before a headache begins (left side), followed by a scotoma drifting across his left visual field from the center toward the periphery over several minutes, just before headache onset. All of these pictures were rated as migraine, both clinically and by drawing.

graine features. Figure 5 shows examples of nonmigraine headaches. Several children drew tight bands or other objects squeezing their heads (Figs 5A and 5B); tight band-like pain is considered pathognomonic of tension-type headaches. Other pictures were less specific, showing general sadness, crying,

or nonspecific pain features (Figs 5D and 5E) or diffuse pain without specific features such as pounding or obvious unilaterality (Figs 5C and 5F).

Aside from the migraine and tension-types, headaches can also be caused by a variety of factors. A 12-year-old girl with pseudotumor cerebri presented




Fig 3. Examples of gastrointestinal symptoms and desire for recumbency. A, An 18-year-old girl describes sharp, pounding pain (arrow) in the right temporal area and nausea depicted by turbulence in her stomach and the aversion to eating (food with slash through). B, A 14-year-old girl illustrates gastrointestinal upset (“yuck!”) associated with left temporal pain. C, An 8-year-old boy illustrates vomiting. He commented, “I sometimes miss the toilet.” D, A 9-year-old boy depicts vomiting. E, A 16-year-old girl lies down and feels left temporal pounding pain (hammer). F, A 9-year-old girl lies down and seems uncomfortable (tears) but shows no other specific migraine features. All of these pictures were rated as migraine, both clinically and by drawing.

with severe headache and diplopia (likely attributable to cranial nerve VI involvement). Her drawing illustrates double vision in astonishing detail, showing separated, side-by-side images (Fig 6A). This picture was classified incorrectly as migraine, probably because of the severe pounding pain from the falling anvil, and was thus a false positive for mi-

graine (see below). Figure 6B shows another example of a symptomatic headache, this one manifest by a dysesthesia with “hot feelings over my neck and back of my head.” This 14-year-old boy was lifting weights when the barbell struck the back of his head, probably causing an injury to the second branch of the right greater occipital nerve (C2); this occipital

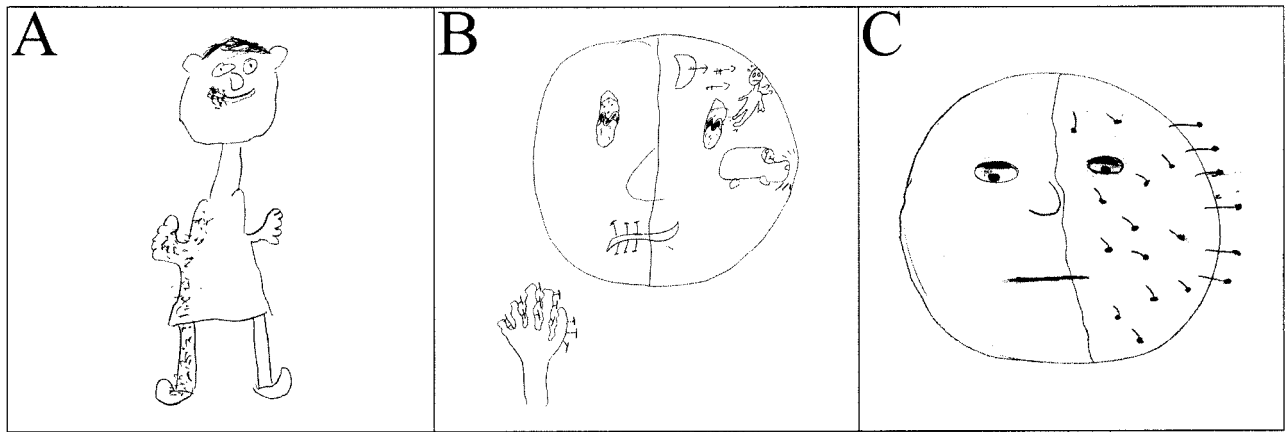


Fig 4. Examples of focal neurologic symptoms. A, A 9-year-old boy with complicated migraine describes focal tingling at the right side of his mouth and entire right trunk, arm, and leg. B, A 17-year-old girl illustrates right face/mouth and hand paresthesias, plus pounding left hemiparesis (“truck smashing into my head”) and “floaty feelings” (figurine “floating” inside head). C, A 13-year-old girl describes “pins and needles” on the left side of her face plus her eye “half-shut with blurry vision” preceding her headache. In B and C, neurologic symptoms perfectly respect the midline. All of these pictures were rated as migraine, both clinically and by drawing.




Fig 5. Examples of nonmigraine headaches. A, A 17-year-old girl shows a tight rope squeezing her head. B, A 10-year-old girl draws a band wrapped around her head, causing what she described as squeezing pain. C, A 17-year-old boy describes bilateral “pulling” in his occipital area and neck, greater on the left side. (Left side: back view; right side: front view.) D, A 6-year-old girl with diagnosis of spinal muscular atrophy type II and recent family stress (parental separation). She expresses profound sadness but no specific migraine features. E, A 10-year-old boy cites nonspecific head pain with no features characteristic of migraine. F, A 9-year-old girl describes pain on the top of her head that is squeezing in nature and increases as the day progresses. None of these diagrams depicts features characteristic of migraine.

neuralgia was associated with a burning sensation (fire). Figure 6C was drawn by a 12-year-old girl with stable, shunted hydrocephalus from aqueductal stenosis. She complained of chronic headaches that felt like “a bubble in the back of my head.” Despite

numerous investigations, shunt malfunction could not be proved.

Figure 7 shows examples of drawings by children who described more than 1 headache type. The girl who drew Figs 7A and 7B likely had previous expo-

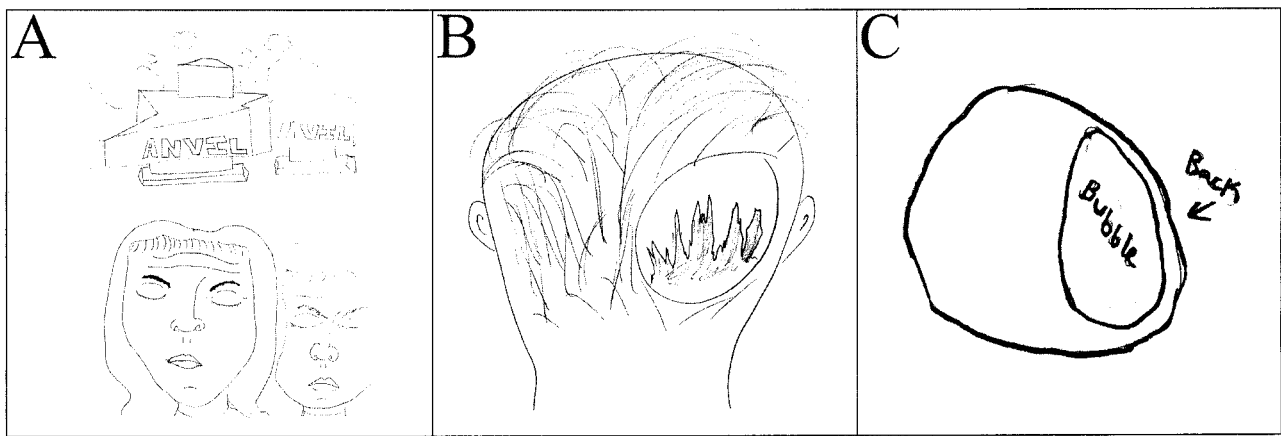


Fig 6. Examples of symptomatic, nonmigraine headaches. A, A 10-year-old girl who presented with headache and diplopia (note double images). Her headache was described as “an anvil hitting my head.” Because of the severity of the pain (anvil), this drawing was rated as consistent with migraine, although clinical evaluation revealed the cause of the headache as pseudotumor cerebri. In retrospect, her diplopia is consistent with a cranial nerve VI palsy, as often seen with pseudotumor cerebri. B, A 15-year-old boy with burning pain over the back of the head. While lifting weights, the barbell came down forcefully on his posterior skull, causing a headache with a burning paresthesia in the C2 distribution. He draws this burning pain as a fire over the C2 region. C, A 14-year-old girl with shunted hydrocephalus describes a several-month history of a headache feeling “like a bubble” located posteriorly over the ventriculoperitoneal shunt site. Evaluation showed intact shunt function, and her headache/bubble feeling persists. Each of these pictures illustrates headaches secondary to a specific cause, not migraine or tension related.

sure to medical descriptions of headache types. Without any prompting, she drew 2 types of headache and labeled them as tension/stress and migraine. The stress headache picture shows her to be in no distress or obvious pain, and she states “not too bad.” Her migraines, however, involve much more severe pain and make it feel like “my head has come off my body.” The male adolescent who drew Figs 7C and 7D likewise described 2 headache types pictorially. In Fig 7C, he is experiencing mild diffuse pain; the migrainous features depicted in his other headache type (Fig 7D) include unilateral pain, left ptosis, and a rainbow-like visual scotoma in the left visual field. These dual pictures illustrate the power of drawings to differentiate between headache types, even in the same patient.

Analysis of Headache Drawings

As described above, certain characteristics were considered a priori to be more consistent with a migraine, including pounding or throbbing nature, visual changes (scotomata, scintillations, fortification spectra, obscuration), nausea, vomiting or other gastrointestinal symptoms, unilaterality, or desire to lie down (recumbency). Other features were considered more consistent with tension-type headache, such as a tight band around the head or diffuse, nonlocalizable pain. Still other features were considered non-specific, such as crying or sad facial expression. Many drawings contained more than 1 feature (eg, pounding pain plus recumbency in Fig 3E).

We analyzed quantitatively the usefulness of children’s drawings to differentiate migraine headaches from headaches of other causes. The κ score for interrater agreement was 0.92, within the “excellent agreement” range (0.81–1.0) defined by Landis and Koch.⁴⁷ Therefore, all drawings were included in the analysis.

Table 1 summarizes the clinical and artistic diag-

noses. From these data, we calculated that headache drawings have a sensitivity of approximately 93% and a specificity of almost 83% when compared with the clinical diagnosis (the “gold standard”). The positive and negative predictive values were 87.1% and 90.6%, respectively. That is, a drawing with migraine features has approximately an 87% likelihood of correctly predicting the clinical diagnosis of migraine, whereas a drawing without migraine features is almost 91% likely to correctly exclude the clinical diagnosis of migraine. The PLR expresses the odds that a child who drew a picture with migraine features actually had clinical migraine. In our study, the PLR for migraine was 9.29, indicating that there is a more than a 9-fold greater chance that a child who drew migraine features had a clinical migraine rather than a nonmigraine headache.

Table 2 lists various features encountered in headache drawings. From these data, we determined the positive predictive value (PPV) of various headache characteristics with regard to migraine; ie, if a certain feature is present in a drawing, the likelihood that the child will have a clinical diagnosis of migraine. Drawings of focal neurologic signs and periorbital pain predicted clinical migraine in all cases. Although a small number, it is not surprising that these features are highly associated with migraine and that raters correctly categorized these pictures as migraine. Recumbency; visual phenomena such as scotomata, obscurations, visual field defects, and photophobia; and gastrointestinal symptoms such as nausea or vomiting also correlate closely with a migraine clinical diagnosis, with PPVs exceeding 90%. Pounding or throbbing pain is often considered characteristic of migraine headaches. However, this artistic feature is somewhat less predictive of migraine in our study, despite being the most frequently drawn feature (125 pictures). Approximately 17% of chil-

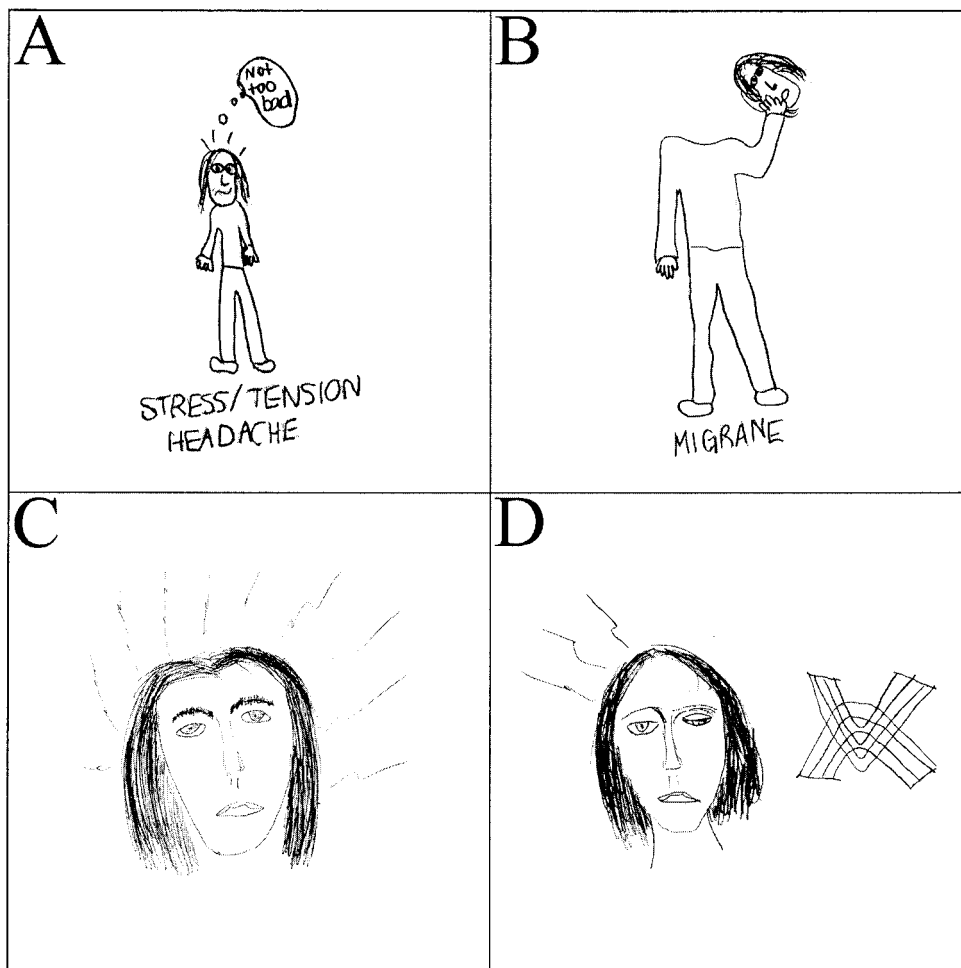


Fig 7. Drawings by children who described 2 types of headache. In each case, diffuse, mild head pain (A, C) was drawn distinct from more severe headache that was consistent with migraine. A and B, A 12-year-old girl draws (and even labels!) her 2 headache types. In A, the pain is diffuse and mild. In B, her head feels like "it has come off my body." C and D, A 16-year-old boy similarly draws mild nonlocalizable pain (C) and more severe, unilateral pain (lines) accompanied by visual blurring (left eye nearly closed) and a rainbow-like scotoma in the left visual field. These examples attest to the ability of drawings to distinguish multiple headache types in the same patient.

TABLE 1. Comparison of Clinical and Drawing Diagnoses of Headache ($n = 235$ Drawings)

Drawing Diagnosis	Clinical Diagnosis	
	Migraine	Not Migraine
Positive test (migraine features)	True positive 69 girls + 52 boys = 121	False positive 7 girls + 11 boys = 18
Negative test (no migraine features)	False negative 6 girls + 3 boys = 9	True negative 45 girls + 42 boys = 87

Sensitivity: $TP/(TP + FN) = 121/130 = 93.1\%$.

Specificity: $TN/(TN + FP) = 87/105 = 82.7\%$.

Predictive value of a positive test: $TP/(TP + FP) = 121/139 = 87.1\%$.

Predictive value of a negative test: $TN/(TN + FN) = 87/96 = 90.6\%$.

PLR: $\{TP/(TP + FP)\}/\{1 - [TN/(TN + FN)]\} = 9.29$.

dren with nonmigraine headaches drew pictures showing severe or pounding pain.

Artistic renderings of dizziness, sadness, or crying poorly differentiated migraines from nonmigraines, each present in pictures of approximately 50% to 65% of children with clinical migraine. Similarly, the location of pain on drawings, including unilaterality, was not useful for headache differentiation. Finally, depiction of a tight band around the head was negatively correlated with migraine, as expected. Such

squeezing pain is characteristic of muscle tension-type headaches, and only 1 of 9 children who illustrated pain in this manner had migraine.

Relationship of Age to Drawings

It might be predicted that the ability to differentiate headache types artistically would be dependent on age. Just as younger children would have less sophisticated verbal explanations of headache features, their immature drawing skills might not allow

TABLE 2. Features of Headache Drawings

Drawing Feature	PPV for Migraine [TP/(TP + FP)]
Focal neurologic signs	7/7 = 100%
Periorbital pain, sharp object to eye	8/8 = 100%
Sleep/recumbency	20/21 = 95.2%
Visual symptoms: scotoma, field defect	19/20 = 95%
Visual symptoms: photophobia	21/23 = 91.3%
Nausea, vomiting	10/11 = 90.9%
Severe, pounding/throbbing pain	104/125 = 83.2%
Sonophobia	4/5 = 80%
Dizziness	11/17 = 64.7%
Pain location	
Unilateral	35/55 = 63.6%
Bilateral/diffuse	43/78 = 55.1%
Midfrontal	14/25 = 56%
Tears/crying	12/20 = 60%
Confusion, poor concentration	2/4 = 50%
Sad expression	35/71 = 49%
Band around head/squeezing	1/9 = 11.1%

TP indicates a drawing that contains the specified feature plus a clinical diagnosis of migraine; TP + FP, all drawings that contain the specified feature.

Note: TP and FP, as defined for the purposes of this table only, represent pictures containing the specified artistic feature. Therefore, the TP and FP here are not the same as in Table 1.

reliable differentiation of migraine versus nonmigraine. This hypothesis was tested by analyzing pictures as a function of age. Children were arbitrarily divided into 3 age groups: early childhood (prelogical or preoperational thinking, <8 years), preadolescence (concrete logical thinking, 8–10 years), and adolescence (formal logical thinking, ≥11 years).⁴⁸ Contrary to expectation, we found that the percentage of discordances (false positives plus false negatives) was actually lowest in the youngest age group. In children younger than 8 years, 5.6% (2/36) of pictures received ratings of false positive or negative for migraine, whereas this rate was 11.0% (9/82) in the 8- to 10-year-old group and 13.7% (16/117) in children 11 years or older. Therefore, this technique should be useful at all ages. Our youngest patient was 4 years old; even this boy drew rocks pounding his forehead (not shown), suggesting migraine.

Breakdown by age, clinical diagnosis, and drawing diagnosis is given in Table 3. The percentage of migraine, both clinically and in drawings, increases with age in both boys and girls. As expected, the highest proportion of clinical migraine occurred in adolescent females. In boys 8 years and older, higher percentages of participants drew migraine pictures than had migraine clinical diagnoses. We surmised that this trend was attributable to the tendency of boys to express severe or violent pain more graphi-

cally. However, review of the pictures did not confirm this hypothesis; girls' depictions of pain intensity were equivalent to those of boys.

Headache Causes in Children Whose Drawings Did Not Contain Migraine Features

Among children whose drawings were rated as nonmigraine, a variety of causes or associated conditions were found. Of the 96 nonmigraine (negative) drawings, 9 were false negatives (children who drew nonmigraine pictures but who received a clinical diagnosis of migraine). Thirty-one drawings were scored as consistent with tension-type headache and/or depression, including posttraumatic stress disorder and other psychogenic causes. Six children had previous head trauma, and 2 had tumors (1 status post medulloblastoma, 1 with a benign but painful skull cyst that presented as a headache). Two children had headaches in the context of an acute viral illness, and 2 had headaches accompanying vertigo (presumed labyrinthitis). Three children in this group had pseudotumor cerebri (discussed below). Finally, a number of other causes affected 1 child each: Arnold-Chiari type I malformation, neurofibromatosis type 1, multiple sclerosis, eye strain, sinusitis, presumed shunt-related malfunction (Fig 6C), and cervical cranial neuritis (Fig 6B). The cause in the remainder of the children is unknown.

TABLE 3. Clinical and Drawing Diagnoses of Headache (*n* = 235)

Age (Years)	Clinical Diagnosis		Drawing Diagnosis	
	Migraine	Nonmigraine	Migraine	Nonmigraine
Boys				
<8	8 (34.8%)	15	7 (30.4%)	16
8–10	18 (56.3%)	14	22 (68.8%)	10
≥11	29 (54.7%)	24	33 (62.3%)	20
Girls				
<8	3 (23.0%)	10	2 (15.4%)	11
8–10	11 (45.8%)	13	9 (37.5%)	15
≥11	61 (67.8%)	29	66 (77.3%)	24
Total	130 (55.3%)	105	139 (59.1%)	96

Values in parentheses are percentages of migraine within each category.

Headache Pictures in Children With the Clinical Diagnosis of Pseudotumor Cerebri

Seven children (2 boys, 5 girls) in our study had the clinical diagnosis of pseudotumor cerebri (idiopathic intracranial hypertension), forming a distinct subgroup of symptomatic, nonmigraine headache. Four drawings were scored as migraine, the most graphic of which is Fig 6A. The diagnosis of pseudotumor cerebri with cranial nerve VI palsy might have been made on the basis of the drawing if the raters had realized that the child was illustrating diplopia. The 3 other pictures in this subgroup (not shown) rated as migraine showed the child's head as an expanding balloon under pressure, blurry vision, and hammer-induced pain, respectively. The remaining 3 pictures drawn by children with pseudotumor did not depict migraine features. Therefore, children with headache attributable to pseudotumor cerebri depicted their headaches in a variety of ways, either with or without migraine features.

DISCUSSION

Our results show that children's drawings have a high degree of specificity and sensitivity in differentiating migraine from nonmigraine headaches. The excellent PPV and PLR for migraine suggests that pictorial representations of migraine features correlate very highly with the clinical diagnosis of migraine. Our findings suggest that this simple, inexpensive technique can be applied in the clinical setting as an adjunctive aid in headache differential diagnosis. To our knowledge, this is the first attempt to analyze children's headache drawings systematically and quantitatively. Several methodological issues warrant discussion.

First, the drawings were obtained in an unbiased manner as possible. The children were asked to produce their drawing before any headache history was obtained, and they were not led with questions such as, "Does your headache feel like pounding pain or squeezing pain?" However, we do not suggest that the children were free of bias. Most children had been evaluated previously by another physician and were probably asked such questions. The print and electronic media might also have influenced the children, eg, television commercials and magazine advertisements for analgesics show intense depictions of headache pain with lightening bolts, hammers, etc. Obviously, we cannot control for such external influences, yet we believe that children can arrive at their own conclusions in describing their pain through art. The presence of a wide range of artistic depictions and our ability to differentiate migraine and nonmigraine headaches so well attests to the ability of children to depict their symptoms accurately.

Second, children's drawings are obviously a product of their innate talent as well as age-related maturation of artistic skills. We anticipated that there would be a higher proportion of discordances (false positives, false negatives) in younger children, but this was not the case. In fact, the discordance rate increased with age. Although not every picture by a

young child is informative diagnostically, we recommend that the method at least be tried in children of all ages. We obtained useful information even in children as young as 4 years.

We divided our participants into 3 age groups, correlating with approximate stages of cognitive development.⁴⁹ Although somewhat arbitrary, this stratification on the basis of age allowed us to compare how well drawings at each cognitive stage allowed determination of headache type. Below 8 years of age (prelogical or preoperational stage), children do not yet fully grasp the relationship between cause and effect and are likely to define pain as having aversive qualities and in simple perceptual terms such as "pain is a hurting thing and you don't like it"⁴⁸ or pain is "in my head." We found that even in this young age group, children depicted pain adequately. Even when drawing human figures in a rudimentary manner (eg, arms and legs emanating from the head rather than from the trunk), children expressed their headache pain in a clear way (eg, showing the head being pounded by a hammer). Children from 8 to 10 years of age (concrete logical stage) begin to understand the variability of pain in terms of duration, quality, and affective consequences. They learn to describe pain in qualitative and quantitative terms beyond simply "it hurts" and begin to devise coping strategies to relieve the pain. Pain changes from a "thing" to a "feeling."⁵⁰ In adolescents, age 11 and older (formal operational stage), children learn to think about pain in more introspective and abstract ways. Psychological aspects of pain take on increasing importance, in addition to physical aspects. In our experience, children's drawings become progressively more sophisticated with age, but in all age groups, artistic features consistent with migraine versus nonmigraine could be discerned. These pictures represent a rich opportunity to explore the cognitive-artistic relationship with regard to the developmental understanding of pain (in preparation).

Third, the omission of colors in the drawings was deliberate. Previous studies using children's pain drawings have allowed the use of colored pencils or markers. For example, use of the colors red and black have been most frequently associated with severe pain.^{37,51-53} Although the use of colors would have added another dimension to our data, we chose to omit colors to achieve a uniformity among drawings by children over a wide age range. Nevertheless, when adopting this method in the clinic, there is certainly no reason that colors should not be used.

We found that the most informative drawing features for the diagnosis of migraine were focal neurologic symptoms, periorbital pain, sleep/recumbency, and visual symptoms. All of those features had PPVs for migraine exceeding 90%. Pounding pain or pain of severe intensity were also useful features to predict migraine, although nearly 20% of such pictures were drawn by children who received a diagnosis of nonmigraine headaches. Tight or band-like pain was much more predictive of nonmigraine headache, as this pain descriptor is characteristic of tension-type headaches. Facial expressions of sadness or distress,

depicted by frowns, crying, and so forth, were seen in nearly equal numbers of children who received a diagnosis of migraine and nonmigraine headache. Therefore, these features do not differentiate headache type sufficiently. Finally, the location or localization of pain on drawings was not useful for headache differentiation, possibly because of 2 factors. First, whereas migraine in adults is typically unilateral, many childhood migraines are bilateral.¹⁰ Only 22% of children with migraine had unilateral headache in Barlow's study.¹² It has been suggested that the IHS criteria be modified to "bilateral or unilateral location" for childhood migraine.¹⁶ Second, the inability of pain location on drawings to predict migraine is partly attributable to our method of analysis. Any picture showing the child holding 1 side of his or her head or showing an object inflicting pain on only 1 side was rated as unilateral. However, many of those headaches were actually bilateral, as determined by questioning the child about his or her drawing after the clinical diagnosis was made. (This information was not conveyed to the raters.)

Our study adds a new dimension to the small but growing literature on headache art. In adults, the migraine art competitions of the 1980s produced a collection of 562 pictures that are yielding a wealth of information about the inner experience of headache. Podoll and Robinson³⁴ analyzed subsets of these pictures, including out-of-body experiences, cenesthasias (bodily sensations that are so unlike previously experienced symptoms that they are difficult to describe),³³ and macro- or microsomatognosia (disorders of the perception of body size).³⁶ Such analyses could provide insights into migraine pathophysiology in terms of how the brain produces such visual images, as well as self-image abnormalities and other psychological suffering of individual migraineurs.

In children, 4 studies analyzed headache drawings.^{37,38,52,53} Unruh et al³⁷ had children with recurrent migraine headaches or chronic musculoskeletal pain draw 2 pictures: 1 of the pain itself and the other of the child him- or herself in experiencing pain. Children with migraine tended to draw a picture of themselves trying to relieve the pain. There were no differences according to gender or age. Lewis et al³⁸ had children from primary care pediatric clinics draw a picture of their headache. The majority of these children (93%) had migraine. The goal of the study was to determine what children wanted to know when presenting with headache to a physician. The authors concluded that children want to know the cause of their headaches and how to relieve the pain and to be reassured that they had no life-threatening illness. In another study, pain intensity was examined in children's headache pictures, compared with a verbal rating scale; raters were unable to differentiate consistently headaches of moderate versus severe intensity.⁵³ Some reports have used children's drawings to illustrate the visual auras of migraine.^{39,40} Hachinski's classic study of visual aura divided children's drawings into 3 categories: binocular visual impairment scotomas, visual distortions and hallucinations, and unocular visual impairment and scotomas. We observed all 3 categories in our

drawings. Other publications have included children's headache drawings as anecdotes to illustrate pain severity,⁴¹⁻⁴³ but these drawings were not analyzed quantitatively. To our knowledge, no quantitative study in the adult or pediatric literature has examined whether headache pictures can differentiate headache types.

CONCLUSION

We encourage clinicians to adopt this simple, inexpensive, and accurate method as a powerful adjunctive aid for headache differential diagnosis in the clinical setting. Our results attest to the usefulness of children's drawings as an adjunct to clinical criteria in pediatric headache evaluation. We do not propose that drawings alone be used to make headache diagnoses. Our method can be applied in conjunction with existing diagnostic criteria in the clinical setting to support and assist the clinical impression. Drawings can be completed in the waiting room or in the examining room before the examiner arrives (directions could be given by the receptionist or nurse). For the vast majority of children, headache drawing is an enjoyable exercise that allows the opportunity to express their symptoms and feelings and may afford greater insight into their pain.

ACKNOWLEDGMENT

We thank Dr N. Paul Rosman for a critical review of the manuscript and helpful suggestions.

REFERENCES

1. Bille B. Migraine in school children. *Acta Paediatr Scand.* 1962;51(suppl 136):1-151
2. Linet MS, Stewart WF. Migraine headache: epidemiologic perspectives. *Epidemiol Rev.* 1984;6:107-139
3. Mortimer MJ, Kay J, Jaron A. Epidemiology of headache and childhood migraine in an urban general practice using ad hoc, Vahlquist and IHS criteria. *Dev Med Child Neurol.* 1992;34:1095-1101
4. Abu-Arefeh I, Russell G. Prevalence of headache and migraine in schoolchildren. *Br Med J.* 1994;309:765-769
5. Lee LH, Olness KN. Clinical and demographic characteristics of migraine in urban children. *Headache.* 1997;37:269-276
6. Sillanpaa M, Antilla P. Increasing prevalence of headache in 7-year-old school children. *Headache.* 1996;36:466-470
7. Rozen TD, Swanson JW, Stang PE, McDonnell SK, Rocca WA. Increasing incidence of medically recognized migraine headache in a United States population. *Neurology.* 1999;53:1468-1473
8. Rothner AD. The evaluation of headaches in children and adolescents. *Semin Pediatr Neurol.* 1995;2:109-118
9. Vahlquist B. Migraine in children. *Int Arch Allergy.* 1955;7:348-352
10. Prensley AL, Sommer D. Diagnosis and treatment of migraine in children. *Neurology.* 1979;29:506-510
11. Headache Classification Committee of the International Headache Society. Classification and diagnostic criteria for headache disorders, cranial neuralgias, and facial pain. *Cephalalgia.* 1988;8(suppl 7):1-96
12. Barlow CF. *Headaches and Migraine in Childhood.* Oxford, United Kingdom: Spastics International Medical Publications; 1984
13. Scheller JM. The history, epidemiology, and classification of headaches in childhood. *Semin Pediatr Neurol.* 1995;2:102-108
14. Metsahonkala L, Sillanpaa M. Migraine in children. *Cephalalgia.* 1994; 14:285-290
15. Seshia SS, Wolstein JR. International Headache Society classification and diagnostic criteria in children: a proposal for revision. *Dev Med Child Neurol.* 1995;37:879-882
16. Winner P, Martinez W, Mate L, Bello L. Classification of pediatric migraine: proposed revisions to the IHS criteria. *Headache.* 1995;35: 407-410
17. Raieli V, Raimondo D, Gangitano M, D'Amelio M, Cammalleri R, Camarda R. The IHS classification criteria for migraine headaches in adolescents need minor modification. *Headache.* 1996;36:362-366

18. Wober-Bingol C, Wober C, Wagner-Ennsgraber C, et al. IHS criteria for migraine and tension-type headache in children and adolescents. *Headache*. 1996;36:231–238
19. Seshia SS, Wolstein JR, Adams C, Booth FA. International Headache Society criteria and childhood headache. *Dev Med Child Neurol*. 1994;36:419–428
20. Fenichel GM. Migraine as a cause of benign paroxysmal vertigo of childhood. *J Pediatr*. 1967;71:114–115
21. Elser JM, Woody RC. Migraine headache in the infant and young child. *Headache*. 1990;30:366–368
22. Barlow CF. Migraine in the infant and toddler. *J Child Neurol*. 1994;9:92–94
23. Chu ML, Shinnar S. Headaches in children younger than 7 years of age. *Arch Neurol*. 1992;49:79–82
24. Rae WA. Analyzing drawings of children who are physically ill and hospitalized, using the ipsative method. *Child Health Care*. 1991;20:198–207
25. DiLeo JH. *Children's Drawings as Diagnostic Aids*. New York, NY: Brunner/Mazel; 1973
26. Klepsch M, Logie L. *Children Draw and Tell: An Introduction to the Projective Uses of Children's Human Figure Drawings*. New York, NY: Brunner/Mazel; 1982
27. Sturmer RA, Rothbaum F, Visintainer M, Wolfer J. The effects of stress on children's human figure drawings. *J Clin Psychol*. 1980;36:324–331
28. Gabriels RL, Wamboldt MZ, McCormick DR, Adams TL, McTaggart SR. Children's illness drawings and asthma symptom awareness. *J Asthma*. 2000;37:565–574
29. Stefanatou A, Bowler D. Depiction of pain in the self-drawings of children with sickle cell disease. *Child Care Health Dev*. 1997;23:135–155
30. Peterson LW, Zamboni S. Quantitative art techniques to evaluate child trauma: a case review. *Clin Pediatr*. 1998;37:45–51
31. Villamira MA, Occhiuto MG. Psychological aspects of pain in children, particularly relating to their family and school environment. In: Rizzi R, Visentin M, eds. *Pain. Proceedings of the Joint Meeting of the European Chapters of the International Association for the Study of Pain, May, 1983*. Padua, Italy: Piccin/Butterworth; 1984:285–289
32. Wilkinson M, Robinson D. Migraine art. *Cephalalgia*. 1985;5:151–157
33. Podoll K, Bollig G, Vogtmann T, Pothmann R, Robinson D. Cenesthetic pain sensations illustrated by an artist suffering from migraine with typical aura. *Cephalalgia*. 1999;19:598–601
34. Podoll K, Robinson D. Out-of-body experiences and related phenomena in migraine art. *Cephalalgia*. 1999;19:886–896
35. Podoll K, Robinson D. Illusory splitting as visual aura symptom in migraine. *Cephalalgia*. 2000;20:228–232
36. Podoll K, Robinson D. Macrosomatognosia and microsomatognosia in migraine art. *Acta Neurol Scand*. 2000;101:413–416
37. Unruh A, McGrath P, Cunningham SJ, Humphreys P. Children's drawings of their pain. *Pain*. 1983;17:385–392
38. Lewis D, Middlebrook M, Mehallick L, Rauch T, Deline C, Thomas E. Pediatric headaches: what do the children want? *Headache*. 1996;36:224–230
39. Hachinski VC, Porchawka J, Steele JC. Visual symptoms in the migraine syndrome. *Neurology*. 1973;23:570–579
40. Lewis D. Migraine and migraine variants in childhood and adolescence. *Semin Pediatr Neurol*. 1995;2:127–143
41. McGrath PJ. Migraine headaches in children and adolescents. In: Firestone P, McGrath PJ, Feldman W, eds. *Advances in Behavioral Medicine for Children and Adolescents*. Hillsdale, NJ: Lawrence Erlbaum Associates; 1982:39–57
42. McGrath PJ, Unruh AM. *Pain in Children and Adolescents*. New York, NY: Elsevier; 1987
43. Ross DM, Ross SA. *Childhood Pain: Current Issues, Research, and Management*. Baltimore, MD: Urban & Schwarzenberg; 1988
44. Stafstrom CE. Usefulness of children's drawings in the diagnosis of migraine. *Neurology*. 1997;48:A260
45. Feinstein AR. *Clinical Epidemiology*. Philadelphia, PA: WB Saunders Company; 1985
46. Maytal J, Young M, Shechter A, Lipton RB. Pediatric migraine and the International Headache Society (IHS) criteria. *Neurology*. 1997;48:602–607
47. Landis RJ, Koch GG. The measurement of observer agreement for categorical data. *Biometrics*. 1977;33:159–174
48. Gaffney A. Cognitive developmental aspects of pain in school-age children. In: Schechter NL, Berde CB, Yaster M, eds. *Pain in Infants, Children, and Adolescents*. Baltimore, MD: Williams & Wilkins; 1993:75–85
49. Piaget J, Inhelder B. *The Psychology of the Child*. London, United Kingdom: Routledge and Kegan Paul; 1969
50. Gedally-Duff V. Developmental issues: preschool and school-age children. In: Bush JP, Harkins SW, eds. *Children in Pain: Clinical and Research Issues from a Developmental Perspective*. New York, NY: Springer-Verlag; 1991:195–229
51. Scott R. It hurts red: a preliminary study of children's perception of pain. *Percept Mot Skills*. 1978;47:787–791
52. Jeans ME. Pain in children—a neglected area. In: Firestone P, McGrath PJ, Feldman W, eds. *Advances in Behavioral Medicine for Children and Adolescents*. Hillsdale, NJ: Lawrence Erlbaum Associates; 1983:23–37
53. Kurylyszyn N, McGrath PJ, Cappelli M, Humphrey P. Children's drawings: what can they tell us about intensity of pain? *Clin J Pain*. 1987;2:155–158

CEREBRAL PALSY RISK AND BIRTH WEIGHT

“The rate of cerebral palsy among surviving children [in the UK] who weighed under 1500 g at birth is nearly 80 times that of babies born weighing over 2500 g. Babies born weighing between 1500 and 2499 g at birth have a rate of cerebral palsy 10 times higher than that of babies weighing >2500 g, but they contribute as many children to the cerebral palsy register as the very low birth weight (less than 1500 g) group.”

Report 2000. Surveillance of Cerebral Palsy. .National Perinatal Epidemiology Unit. E-mail: general@perinat.ox.ac.uk

Submitted by Student